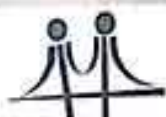

Patient Name – Anjali Kumari / Father's Name – Vijay Prasad





Registration Form



* Patient Full Name ANJALI KUMARI

* Patient's Date of Birth 01.11.2008 Age 12

* Patient's Gender FEMALE

* Patient's Guardian Name MR. VIJAY PRASAD

* Relation With Child FATHER

* Permanent Address WARD-16, LUCANAMA TOLA, CHAMPARNA

..... 1st WARD CHAMPARNA

Dist. CHAMPARAN Pin Code 845101 State BIHAR

* Contact Number +91- [REDACTED] ; +91 - [REDACTED]

* Patient's Family Background FARMER

* Parent / Guardian Proof AADHAR

Id No. [REDACTED]

* Hospital Name (where patient admitted) AIIMS HOSPITAL, DELHI

* Name of Department RADIATION ONCOLOGY

* Disease (patient suffering from) EWING'S SARCOMA MYELOPATHY

* Doctor's Name (who treated the patient) Dr. SAMBHU RASTOGI

* OPD Reg. No. 1145-105023391 Date 31.10.2020

* Approximate Treatment Cost 3,00,000/-

[Handwritten Signature]
(Parent / Guardian signature OR L11)

* Registration No. (records in NGO) MH.0078/2021 (Only Office Use)

[Handwritten Signature]
Deputy Officer's Signature

approved
on 08/July/2021

[Handwritten Signature]
Trustee Signature with seal

1993





डा. बी. आर. अम्बेडकर सरथान राष्ट्रीय कर्करोग अस्पताल
Dr. B. R. Ambedkar National Cancer Hospital

OPR-6
Premises

DR. B. R. AMBEDKAR, NEW DELHI

Reg. No. 241372

Reg. Date: 25/01/2020

Unit: Urology & Prostate Cancer Clinic

Clinic No. 1/1/2020

Specialty: MEDICAL ONCOLOGY



एकत/Unit

विभाग/Dept.

नाम/Name

श्री अंजलि अंबेडकर

Name: ANJALI

Y: VIJAY PRASAD

Phone No. 9507607832

Address: CHAMRAN, BIHAR, Pin 0, INDIA

Regn. No.

जन्म तिथि/Date of Birth

Age

रिपोर्ट/Diagnosis

cf. Ewing sarcoma

दिनांक/Date

उपचार/Treatment

Topotecan + cyclo (ctt 1)

(Plan)

3/2/2020

- i/j EMESER 8mg i/v D₁-D₃
- i/j DEXA 8mg i/v D₁-D₃
- i/j CYCLOPHOSPHAMIDE D₁-D₃ → D₁- 2gm, D₂-D₃- 1gm
- i/j MESNA 400mg i/v D₁-D₃
- i/j TOPOTECAN D₁-D₃ D₁- 2mg, D₂-D₃- 1mg

अंगदान-जीवन का बहुमूल्य उपहार/ORGAN DONATION - A GIFT OF LIFE

O.R.B.O., AIIMS, 26588360, 26593444, www.orbo.org Helpline - 1060 (24 hrs service)

रहने से आने वाले रोगियों के लिए अंगदान की सुविधा उपलब्ध है/Dharamshala facility is available for outstation patients



Scanned with CamScanner

T. CHEST 8-00-81 x 33
 ij Cef 300 mg qd D5 ONWARDS x 12
 T. DEPT 8-10-00 x 20
 TO Union 24/2/22 E CEC, NG, US

Pain diet - amc

PML - → + brace

Physio:

3/2/2022 Physiotherapy

- ⇒ Pt clo pain in lower back & neck. 1 pain @ L/L
- Also clo weakness of (L) L/L
- Also do vitamin medical report of (L) lower leg muscles
- ⇒ study ex for (L) L/L as ch
- Quadriceps (L) ex. as ch

	R	(L)
Hg		
K ₁	4/5	2/5
A ₄		

NAME: ANJALI
REFERRED BY: DR. SAMEER RASTOGI

PATIENT ID: DNP/26312/2020

AGE/ SEX: 14 YRS / FEMALE
DATE: 01 FEB 2022

IMPRESSION:

Case of Ewing's sarcoma of paraspinal region (L4 vertebrae), post chemoradiotherapy followed by radiotherapy completed in 27/12/21

As compared to previous scan dated 16/11/21, scan findings reveal;

- Increase in metabolism and size of soft tissue component associated with erosive changes in the transverse process of L3- L4 vertebrae and left side of body of L4 vertebrae as described above.
- No other significant metabolically active disease noted.

Scan findings suggestive of progression.



Dr. ZAEBAN
M.D
Consultant Nuclear Medicine



NAME: ANJALI

PATIENT ID: DNP/26312/2020

AGE/ SEX: 14 YRS / FEMALE

REFERRED BY: DR. SAMEER RASTOGI

DATE: 01 FEB 2022

Clinical Details:

Case of Ewing's sarcoma of paraspinal region (L4 vertebrae), post chemoradiotherapy followed by radiotherapy completed in 27/12/21

Technique:

Approximately 80minutes following intravenous injection of 6.8mCi of 18F-FDG whole body FDG PET/CT scan with contrast(oral and intravenous) was performed from vertex to mid thigh with GE discovery 600 Pet/Ct system without breath-holding instruction. High resolution CT scan was performed using a dedicated PET scanner with 16 slice/sec MDCT. A separate breath hold CT was performed for lung examination. Semi-quantitative analysis of FDG uptake was performed by calculating SUV value corrected for dose administered and patient body weight. The blood sugar at the time tracer injection was 104mg/dl

HEAD AND NECK:

- Brain parenchyma shows physiological tracer uptake. No discrete hypermetabolic lesions seen.

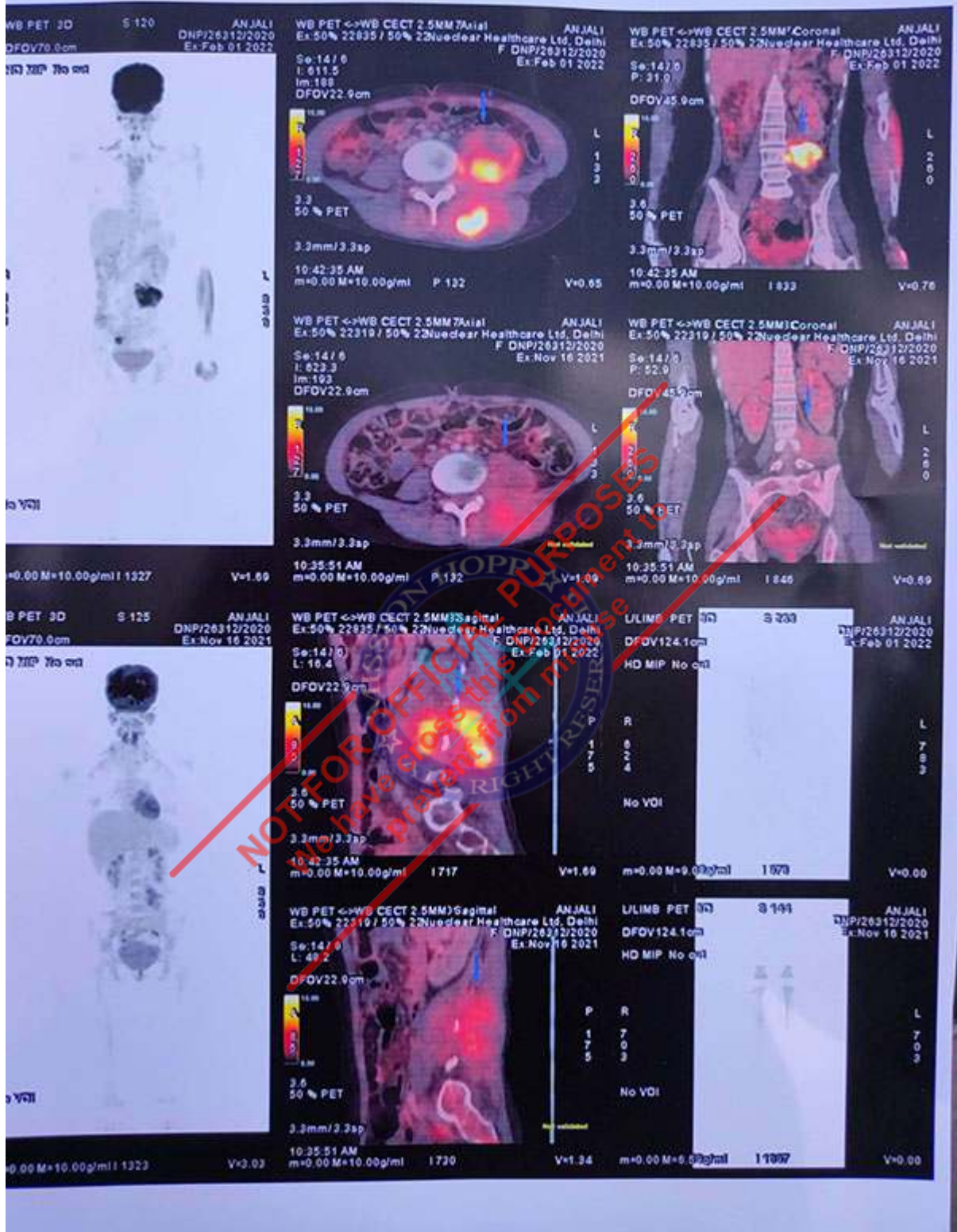
(Note: All brain metastases are not detected on 18-F FDG PET/CT due to physiological uptake in brain. MRI Brain is suggested in case of clinical suspicion)

- Diffuse FDG uptake noted in bilateral palatine tonsil and nasopharynx-appear inflammatory.
- No abnormal enhancing hypermetabolic lesion in hypopharynx.
- No significant FDG avid cervical / supraclavicular lymph nodes seen.
- Both lobes of thyroid gland appear normal in size. No discrete FDG avid hypodense lesion seen.

CHEST:

- Bilateral breast parenchyma appear unremarkable. No focal enhancing /abnormal FDG uptake noted in bilateral breast .
- No interval changes in fibro nodular thickening along the right oblique fissure. Few tiny calcified granuloma is noted in the left lower lobe -unchanged. No discrete FDG avid soft tissue nodules seen in lung parenchyma. No pleural effusion or significant pleural thickening on either side.

Page 1 of 3



CS Scanned with CamScanner

27/9/2017

Swings Samanta (Deceased) (mucopolysaccharidosis)
L4 Vertebrae

Intent - perlestatin

OMIT Actinomycin D
Intrav Repro Cycle

Also :-

- Go for Wk # 24 VAC -> Room No. 10
- (omit Actinomycin - D)
- > Plan to Proceed with Reus
- Continue RADIATION #
- Reus on 4/10/2017 20:00 hrs

25/10/21

Adv :-

- Go ahead with WK # 28 VDC
- 300 mg G-CSF 300 mg qd for 5 days
- FU on 8/11/21 with chemo + FU

To
SR.
dayla

Kindly give next
IE dose on 8/11/21
f/u on 25/11/21

Pharath

Dr. Bharath B.G.

Senior Resident

Department of Medical Oncology

Dr. BRANCH (ARMS), NRI, D-110-11029

Address: 110, 110/110, 110/110/110 S.

Phone: 9876543210

IE
Wk 30 D1
10/11
A

Abhid
Smta

f/u on 3/2/22 in med on C O P D
SHOT ON REDMI 7
AI DUAL

DR. B.R. BHICHAHMS NEW DELHI

ORCH No. 241372
 Chief, The Endocrine Malignancy Clinic
 Dept. MEDICAL ONCOLOGY
 General

Reg. Date: 23/01/20
 Clinic No. 31/050
 UHO-10507/371

OPR-6

आर्य समाज रोगी सं./O.P.D. Regn. No. _____

नाम: अंजलि अंजलि
 Name: ANJALI
 DO-VIDAY PRASAD
 Phone No. 43000023
 Address CHAMRAN, BSIAR, P.O., INDIA

उम्र / Age: 14y

पता / Address: ↓ Dr. Rambha Pandey

रिपोर्ट/Diagnosis: L4 paraspinal Ewing Sarcoma.

दिनांक/Date	उपचार/Treatment
23/12/21	RT planned & received carboplatin RT to L3-L4 vertebral mass lesion by 166/14#1 rule i Full arc VMAT technique w/ 21/12/21 - 27/12/21. No RT toxicity. Adv
23/12/21	① Renew in RN-58 [Thursday] Friday, RN-6, Tuesday 8.30am after 20/12
	② RT to MV after 1 month in PET CT RT 50/6

Kindly provide Railway Concession
 Rules SR/RT

NOT FOR OFFICIAL PURPOSES
 We have cross this document to prevent from misuse



NAME: ANJALI
REFERRED BY: DR. SAMEER RASTOGI

PATIENT ID: DNP/26312/2020

AGE/ SEX: 14 YRS / FEMALE
DATE: 01 FEB 2022

- No significant FDG avid mediastinal lymph nodes seen.

ABDOMEN AND PELVIS:

- Stomach appears unremarkable.
- Liver appears normal in size. No discrete FDG avid hypodense lesion seen. No IHBRD seen. Gall Bladder appears partially distended. No FDG avid lesion noted in gall bladder.
- Spleen appears normal in size. No discrete FDG avid hypodense lesion seen.
- Pancreas appears normal in attenuation with no discrete FDG avid hypodense lesion.
- Visualized loops of large intestine and small intestine appear normal with no mural thickening or mass lesion or focal abnormal FDG uptake.
- Bilateral adrenal glands appear normal in size, morphology and show no focal nodularity/focal abnormal FDG uptake.
- Bilateral kidneys appear normal in size with no focal FDG avid hypodense lesion.
- No significant FDG avid abdominal and pelvic lymph nodes.
- No free fluid in abdomen and pelvis.
- Focal FDG uptake noted in the right adnexa-likely corpus luteum.
- Physiological tracer uptake is seen in myocardium, kidneys, ureters and urinary bladder.

MUSCULOSKELETAL SYSTEM:

- Increase in FDG uptake and size of soft tissue component associated with erosive changes in the transverse process of L3-L4 vertebrae and left side of body of L4 vertebrae measures 9.9x6.8x8.2cm, SUV max 12.32 (previous 6.8x5.1x8cm, SUV max 4.52). Soft tissue component is involving left paraspinal muscles and left psoas.
- Rest of the visualised skeletal system appear unremarkable .

Page 2 of 3



डा. बी. आर. अम्बेडकर संस्थान रोटरी कैंसर अस्पताल
Dr. B.R. Ambedkar Institute Rotary Cancer Hospital

अ.भा.आ.

बहिरंग
अस्पताल के अन्दर

OPR-6

DR. B.R. AMBEDKAR NEW DELHI

IRCH No. 24372

Reg Date 21/01/2009

Class: Laboratory Outpatient

Case No. 109942000

Dept: RADIATION ONCOLOGY



Gender

U888-10303371

/Date of Birth

मान -व्यक्ति जानकारी

Name: ANJALI

DOB: 21/01/1980

Sex/Age: F/33

Phone No. 9107007832

Room + (Shift Morning)

Address CHAMBA, BIRAR, Ph-7, DUDA

एकाद/Unit OPD
विभाग/Dept Med Onc

नाम/Name

रिपोर्ट/Diagnosis

Ewing's sarcoma Lx vertebrae - Default

दिनांक/Date

Week #12 VAC उपचार/Treatment

17/06/21

Tinj Emerit 8 mg

21/06/21

Tinj Dexa 8 mg

Tinj Cap 100 mg po

~~Surveys~~
~~Self Report~~

R.N.A.15

Tinj Cap 100 mg po

Tinj Dexamethasone 8 mg po

Tinj Endoxan 750 mg iv

Tinj Mema 500 mg iv push

Paracetamol

Tinj Aspirin 200 mg qd

T. Emerit 4 mg BD

T. Dexa 4 mg BD

T. Rantac 150 mg BD

Flu in 08/07/21

CSG/UM/FA

x 3 days

CSG/UM/FA

CSG/UM/FA

अंगदान-जीवन का बहुमूल्य उपहार/ORGAN DONATION - A GIFT OF LIFE

O.R.B.O., AIIMS, 26588360, 26593444, www.orbo.org Helpline - 1060 (24 hrs service)

आप से आने वाले रोगियों के लिए धरमशाला की सुविधा उपलब्ध है/Dharamshala facility is available for outstation patients

8/5/2021

→ R1 hypermnesia → ~~10/1/2021~~

Substance has seen → Pet-CT

Seen by RO → JUV. 12/1/2021

Get info/actual

Sub
sent

Reg. the ↓

~~NOT FOR OFFICIAL PURPOSES~~
We have cross this document to prevent from misuse

Friday 8/6/2021

8:30 AM
Count - 6

MISSION HOPP
RIGHT RESERVE

~~NOT FOR OFFICIAL PURPOSES~~
We have cross this document to prevent from misuse



SHOT ON REDMI 7
AI DUAL CAMERA

Rotary Cancer Hospital
/A.I.I.M.S. HOSPITAL

OPR-6

DR. B.R.A. BHALLA, NEW DELHI

RCH No. 241372

Spec. Use Endocrine Malignancy Clinic

Spec. MEDICAL ONCOLOGY

Specialist

Name ANJALI

मम अंजलि अग्रवाल

DO-VEJAY PRASAD

Home No. 8597607872

Address CHAMLAN, BHOK, PUNJ, INDIA

Reg. Date-25/01/2020

Clinic No. 31120209



CHID-105533771

Sex/Age F/47

Home e. (Skill Member)

Out Patient Department
NO PROHIBITED IN HOSPITAL PREMISES

आर्योपेक्षा संकेतक नं./O.P.D. Regn. No.

Sex	Age	जन्म तिथि/Date of Birth
		05/3R

रिपोर्ट/Diagnosis NM - Pancreatic lump.

रिवीज/Date

उपचार/Treatment

08/10/20	Ad	<p> </p> <p> </p> <p> </p>
----------	----	----------------------------

अंगदान-जीवन का बहुमूल्य उपहार/ORGAN DONATION - A GIFT OF LIFE

O.R.B.O., AIIMS, 26588360, 26593444, www.orbo.org. Helpline - 1060 (24 hrs service)

बाहर से आने वाले रोगियों के लिए धरमशाला की सुविधा उपलब्ध है/Dharamshala facility is available for outstation patients



डा. बी. आर. अम्बेडकर संस्थान रोटरी कैंसर अस्पताल
 Dr. B.R. Ambedkar Institute Rotary Cancer Hospital
 अ.भा.आ.स.
 बहिरंग रो
 अस्पताल के अंदर पुया

203936
 (30)

Dr. Anjali S. No
 15/12/20
 OPR-6

एक्टर/Unit B.S. Raslogi
 विभाग/Dept.

IID: 105033371
 RCH No. 241372
 Name ANJALI
 पति विजय प्रसाद
 PO VIJAY PRASAD
 Home No. 9507607032



RT-109994

नाम/Name

Sex/Age F/11Y
 Date of BIRTH

रिपोर्ट/Diagnosis RT-109994 ? Ewing's sarcoma & Compressive Myelopathy

दिनांक/Date
26/01/2020

उपचार/Treatment
Adv. at discharge

- ① Tab Dexa 8mg BD X 5 more days
- ② Tab Dexa 8mg BD X 3 days
- ③ Tab Dexa 8mg BD X 2 days - stop
- ④ Tab Dexa 8mg BD X 2 days - stop
- ⑤ Tab Dexa 8mg BD X 2 days - stop
- ⑥ Tab Dexa 8mg BD X 2 days - stop
- ⑦ Tab Dexa 8mg BD X 2 days - stop
- ⑧ Tab Dexa 8mg BD X 2 days - stop
- ⑨ Tab Dexa 8mg BD X 2 days - stop
- ⑩ Tab Dexa 8mg BD X 2 days - stop
- ⑪ Tab Dexa 8mg BD X 2 days - stop
- ⑫ Tab Dexa 8mg BD X 2 days - stop
- ⑬ Tab Dexa 8mg BD X 2 days - stop
- ⑭ Tab Dexa 8mg BD X 2 days - stop
- ⑮ Tab Dexa 8mg BD X 2 days - stop
- ⑯ Tab Dexa 8mg BD X 2 days - stop
- ⑰ Tab Dexa 8mg BD X 2 days - stop
- ⑱ Tab Dexa 8mg BD X 2 days - stop
- ⑲ Tab Dexa 8mg BD X 2 days - stop
- ⑳ Tab Dexa 8mg BD X 2 days - stop
- ㉑ Tab Dexa 8mg BD X 2 days - stop
- ㉒ Tab Dexa 8mg BD X 2 days - stop
- ㉓ Tab Dexa 8mg BD X 2 days - stop
- ㉔ Tab Dexa 8mg BD X 2 days - stop
- ㉕ Tab Dexa 8mg BD X 2 days - stop
- ㉖ Tab Dexa 8mg BD X 2 days - stop
- ㉗ Tab Dexa 8mg BD X 2 days - stop
- ㉘ Tab Dexa 8mg BD X 2 days - stop
- ㉙ Tab Dexa 8mg BD X 2 days - stop
- ㉚ Tab Dexa 8mg BD X 2 days - stop
- ㉛ Tab Dexa 8mg BD X 2 days - stop
- ㉜ Tab Dexa 8mg BD X 2 days - stop
- ㉝ Tab Dexa 8mg BD X 2 days - stop
- ㉞ Tab Dexa 8mg BD X 2 days - stop
- ㉟ Tab Dexa 8mg BD X 2 days - stop
- ㊱ Tab Dexa 8mg BD X 2 days - stop
- ㊲ Tab Dexa 8mg BD X 2 days - stop
- ㊳ Tab Dexa 8mg BD X 2 days - stop
- ㊴ Tab Dexa 8mg BD X 2 days - stop
- ㊵ Tab Dexa 8mg BD X 2 days - stop
- ㊶ Tab Dexa 8mg BD X 2 days - stop
- ㊷ Tab Dexa 8mg BD X 2 days - stop
- ㊸ Tab Dexa 8mg BD X 2 days - stop
- ㊹ Tab Dexa 8mg BD X 2 days - stop
- ㊺ Tab Dexa 8mg BD X 2 days - stop
- ㊻ Tab Dexa 8mg BD X 2 days - stop
- ㊼ Tab Dexa 8mg BD X 2 days - stop
- ㊽ Tab Dexa 8mg BD X 2 days - stop
- ㊾ Tab Dexa 8mg BD X 2 days - stop
- ㊿ Tab Dexa 8mg BD X 2 days - stop

-CECT c/s/f dated 25/01/20
 - Bone scan dated 06/2/2020
 Get CECT & Bone scan done as dated

- ⑤ RT opinion (in the RNS)
- ⑥ Pending workup - 2d Echo - done @ WPP no SWT
- CECT Chest/abd/Pelvis
- Bone scan
- ⑦ Inf. GCSF 300mg sc. OD X 5 days (R No. 15) DS (29/1/2020) as dated
- ⑧ F/U in OPD (0 E CBA/ETIKP T)

अंगदान-जीवन का बहुमूल्य उपहार/ORGAN DONATION - A GIFT OF LIFE
 O.R.B.O., AIIMS, 26568380, 26593444, www.orbo.org Helpline - 1060 (24 hrs service)
 बाहर से आने वाले रोगियों के लिए धरमशाला की सुविधा उपलब्ध है/Dharamshala facility is available for outstation patients
 ⑨ Syp. Sucralfate 250mg on 30/01/2020

for 1000
14/10/20

3
20/1/20

Adv:

- C/O Paraspinal spine's
& paraparesis

post PAC chemotherapy on 25.1.20

max D+T of chemo

- To meet Dr. [unclear] for Palt RT - 200

(Pt have paraparesis, post chemo
mild paraparesis)

- To control [unclear]

- To control GCSF

- To ELO - 4/2/20

106/10/20
106/10/20 Teaching block,
1st floor
TOC/LFNAC
20/1/20

1/2/20



21/1/20

Dr. [unclear]

21/1/20
To request & on study (15)
[unclear]

Def RT 150.00/20/15/20

To consider initial [unclear] fraction 0.2D
↓ 0.1D
3D conversion in

→ [unclear]
→ [unclear] in [unclear] on 3/2/20 @ 8:30am
[unclear]

days
days
days

अखिल भारतीय आयुर्विज्ञान संस्थान, नई दिल्ली
ALL INDIA INSTITUTE OF MEDICAL SCIENCES, NEW DELHI
NATIONAL CANCER INSTITUTE

LNID	105033371	Name	Miss ANJALI AGARWAL
Age	15 years 2 months 2 days	Sex	Female
Reg Date		Verification Time	24/05/2021 02:22 pm
Ward Name		Lab Ref No.	300
Unit Name	Link	Unit Incharge	Dr. Lata Kumar (HOC)
Department	Medical Oncology	Sample Collection Date	24/05/2021 08:25 am
Lab Name	NCI CORE LAB	Lab Sub Centre	
Report Generated Date	24/05/2021 02:21 pm	Dept / RCH No.	241372
Recommended By	Dr. Aditi	Sample Received Date	24/05/2021 12:33 PM

Sample Details : E240321110

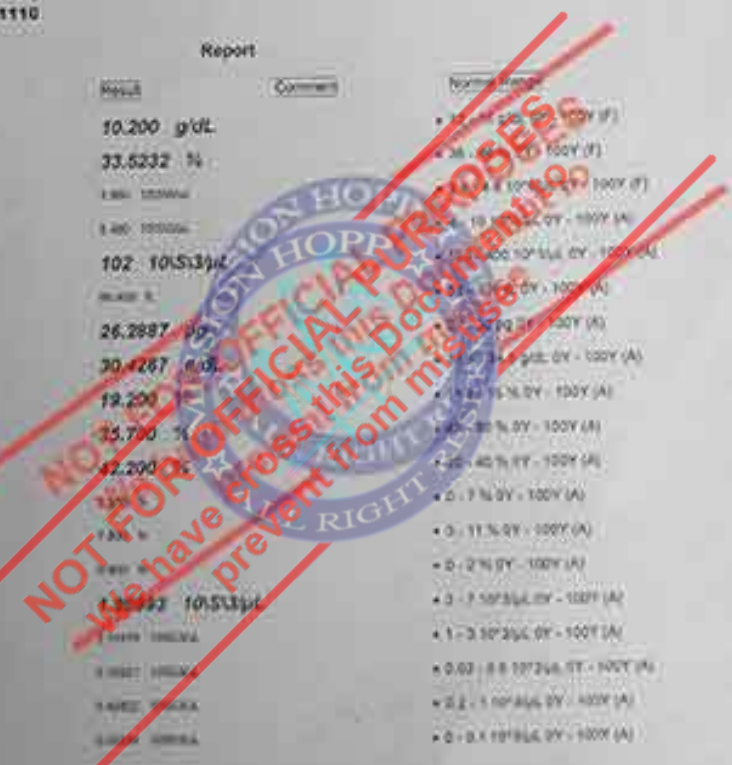Report

Test Name	Result	Comment	Normal Range
Hemoglobin	10.200 g/dL		• 12.0 - 15.0 g/dL (F)
Hematocrit	33.5232 %		• 36.0 - 47.0 % (F)
RBC Count	4.90 1000000		• 4.0 - 5.4 x 10 ⁶ /L (F)
WBC Count	4.40 1000000		• 4.0 - 10.0 x 10 ⁹ /L (A)
Platelet Count	102 101513/pl		• 150 - 400 10 ⁹ /L (A)
RDW	16.40 %		• 11.5 - 14.5 % (A)
MCH	26.2887 pg		• 27.0 - 32.0 pg (A)
MCHC	30.4267 g/dL		• 32.0 - 36.0 g/dL (A)
RDW	19.200 %		• 11.5 - 14.5 % (A)
Neutrophils	35.700 %		• 40 - 80 % (A)
Lymphocytes	42.200 %		• 20 - 40 % (A)
Eosinophils	3.300 %		• 0 - 7 % (A)
Monocytes	7.300 %		• 0 - 11 % (A)
Basophils	1.500 %		• 0 - 2 % (A)
Neutrophils - Abs	1.58932 101513/pl		• 0 - 7 10 ⁹ /L (A)
Lymphocytes - Abs	1.8468 101513/pl		• 1 - 3.50 10 ⁹ /L (A)
Eosinophils - Abs	0.14662 101513/pl		• 0.02 - 0.8 10 ⁹ /L (A)
Monocytes - Abs	0.32562 101513/pl		• 0.0 - 1.0 10 ⁹ /L (A)
Basophils - Abs	0.0660 101513/pl		• 0 - 0.1 10 ⁹ /L (A)

Overall Comment :

Authorized Signature
[]

Signed By
[Latahoppalshetti]



- Tab Dexa 8mg OD X 3 days
- Tab Emetet 8mg BD X 3 days
- Tab Pantop 40mg OD BBF X 3 days

- To f/u in R.T. (Tue/Fri) @
 Dr. Rambha Pandey Malam for
 initiating definitive R.T.

- PET-DIRC (for intermuscular uptake)

- F/U - on 12/04/2021 CBC/LFT/KFT

CD - Raj kamani OD
 Gaurav Jais
 PET-CT Room (2.5/F)

Rambha Pandey
 on 13/4/21

Shravan
 31/10

Kindly accommodate
 in Dharamshala
 Shravan

NOT FOR OFFICIAL PURPOSES
 We have cross this document to prevent from misuse

12/4/21

① US guided bx from Rt thigh - medial aspect. Cornea fall

② Bx core fall for IT on 19/4/21
 F/U on 19/4/21 @ LFT/KFT

13/4/21

③ Biopsy of back mass more amenable - deti given for biopsy of thigh lesion appear more like a collection

19/04/2021

CBC/IT/INR/LFT/KFT
 COVID RT-PCR PNA
 F/U - 22/4/2021

D/C date after 23rd

3 days
+ 3 days

डा. बी. आर. अम्बेडकर संस्थान रोटरी कैंसर अस्पताल
Dr. B.R. Ambedkar Institute Rotary Cancer Hospital

अ.भा.आ.स.

OPR-6

नहिरग रो
अस्पताल से अन्दर प्रवेश

DR. B.R.A. BICHAHNS, NEW DELHI

रोग/Unit DRSR
विभाग/Dept. Med Onc

IRCH No. 241372
Clinic: The Endocrine Malignancy Clinic
Dept. MEDICAL ONCOLOGY
General

Reg. Date-25/01/2008
Clinic No. 111/2008



UTHD-105033371

Date of Birth

रोग/Name

Name ANJALI

नाम अंजलि अजलि

EDU-VDAY PRASAD

Sex/Age F/44Y

Phone No. 990607832

Room 6 (SMB Meeting)

Address CHAMKAN, BHOJAL, Post, DELHI

5/3/12
13/4

बिस्तर/Diagnosis

Ewing's sarcoma L4 vt - 2nd attempt

दिनांक/Date

05/04/2021

उपचार/Treatment

Plan: - VAC-50% (wk#8)

- Cap Aprevacap 50mg D1
- Inj. Doxorubicin 100mg D2, D3

- Inj. Vincristine 1mg D1


- Inj. Cyclophosphamide 500mg slow inj. P. D1

- Inj. Prochlorperazine 50mg slow inj. P. D1

- Inj. Endoxan 50mg slow inj. P. D1

- Inj. Mesna 500mg P.V.P. S.M.W.

Post-chemo:
- Inj. G-CSF 200µg S.C.-OD X 6 days
D4 onwards



R.No.15

अंगदान-जीवन का बहुमूल्य उपहार/ORGAN DONATION - A GIFT OF LIFE

O.R.B.O., AIIMS, 26588360, 26593444, www.orbo.org Helpline - 1060 (24 hrs service)

आप से आने वाले रोगियों के लिए परामर्श की सुविधा उपलब्ध है/Dharamshala facility is available for outstation patients



डा. बी. आर.
Dr. B.R. Amb
अ.भा.आ
गहिरं
अस्पताल डी अरु

DR. B.R.A. BHILAIN, NEW DELHI
ICR No. 241377
Chief, The Endocrine Malignancy Clinic
Dept. MEDICAL ONCOLOGY
Genoa
Name अंजलि अंजलि
डॉ. ANJALI
DR. VIJAY PRASAD
Phone No. 93767383
Address CHANDRASEKAR ROAD, PATEL NAGAR

ताल
गितल

OPR-6



रूम/Unit 205R
विभाग/Dept Med Onc

नाम/Name	प्रा./प्रा.वर्ष./प्रा.पुं F/S/W/H/O of	लिंग Sex	उम्र Age	प्रा./प्रा.वर्ष./प्रा.पुं DOB/Date of Birth
Anjali		F	14y	

रोग/Diagnosis Ewing's sarcoma Lt. vt. (curative)

प्रा./प्रा.वर्ष./प्रा.पुं Date	उपचार/Treatment
<u>26/04/2024</u>	Plan: - wk#10 IF - Cap Aprecap 100mg D1, D3 } per chem - 2mg Doxorubicin 100mg D1, D3 } - 2mg Etoposide 100mg D1, D3 } P.V.P. D1-D3 - 2mg Mesna 600mg i.v.p. 0, 4, 8hrs D1-D2 - 2mg Etoposide D1=200mg / 105% D / i.v. 2hr D2=150mg - Post-chemo - 2mg G-CSF 200mg s.c. OD X6d D onwards

nkpr10
26/4

M.S = 5g
22mg = 200mg

Fluoramide 600

Day line
2nd Floor

